

# PTAB With the DETOUR™ System for the Management of Long SFA Disease

Drs. Ajit Rao and Prakash Krishnan discuss their treatment algorithm for patients with long SFA disease, how they manage risk factors, and when to incorporate the DETOUR™ System into practice.



## Ajit Rao, MD, RPVI, FACS

Director of Vascular Surgery Research  
 Director of Vascular Surgery  
 Simulation Center  
 Associate Professor of Surgery and  
 Radiology  
 Icahn School of Medicine at  
 Mount Sinai  
 New York, New York  
*Disclosures: None.*



## Prakash Krishnan, MD, FACC, FSCAI

Director of Endovascular Interventions  
 Co-Director of Complex Coronary &  
 Vascular Cases  
 Professor of Cardiology and Radiology  
 Icahn School of Medicine at  
 Mount Sinai  
 New York, New York  
*Disclosures: None.*

[PTAB], or open surgical revascularization), wound care, and treatment of recurrent disease are often discussed among interventional cardiology, vascular surgery, and podiatry to ensure patients receive the best care possible.

Isolated SFA disease typically presents as claudication initially. Thus, it is important to consider a patient's preference, severity of symptoms, activity level, and anatomic factors to decide on a treatment modality. In general, we consider invasive treatment in patients with severe lifestyle-limiting claudication who have not responded to conservative management.

**What are the clinical or anatomic characteristics that would lead you to intervene on a first-time long SFA lesion patient beyond medical management or exercise regimen? Could you please walk through the treatment strategy and/or algorithm you follow for the first-time long SFA lesion patient?**

Patients with an isolated SFA lesion typically present with claudication. If the patient is presenting for the first time, we generally start with a trial of conservative management. This includes an exercise program as well as medication, dietary, and lifestyle modification, including smoking cessation.

If conservative treatment fails and the patient has severe lifestyle-limiting claudication, we will consider revascularization. Long-segment SFA disease and chronic total occlusions tend to be a more challenging problem to treat in terms of the ability to cross the lesion or obtain a satisfactory angiographic result and long-term patency. We have traditionally offered an endovascular-first approach for these patients, especially in patients without a usable vein. For cases where endovascular treatment fails, we consider open surgical bypass. PTAB

**As a multidisciplinary team, how do you approach treatment decisions for patients with long superficial femoral artery (SFA) disease? How do patient anatomy, lifestyle, and preferences weigh into your decision?**

As there are multiple options to treat SFA disease, collaborating and discussing cases among different specialties enhances the care of our patients with peripheral vascular disease. Initial management (conservative, endovascular, percutaneous transmural arterial bypass

## PTAB WITH THE DETOUR™ SYSTEM

Sponsored by Endologix

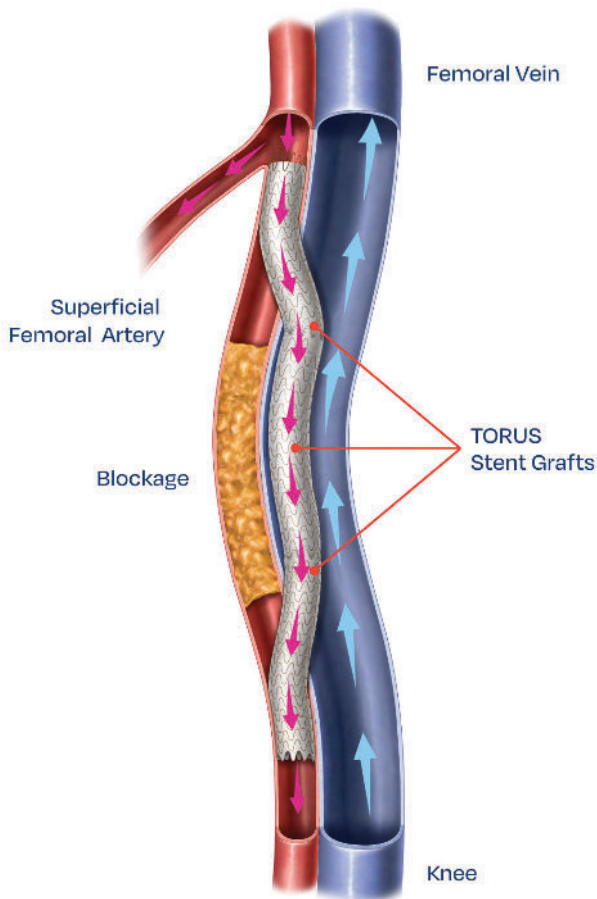


Figure 1. The DETOUR System. The completed procedure redirects arterial blood flow around a long femoropopliteal blockage via the TORUS Stent Graft within the femoral vein, allowing perfusion to the lower extremity distal to the obstruction.

with the DETOUR™ System (Endologix; Figure 1) changes the treatment algorithm and adds another modality to provide a more complete approach to the treatment of long SFA disease.

**Are there any instances where you would seek an alternative approach for a first-time SFA lesion patient or send the patient directly to open femoropopliteal bypass surgery?**

Although many patients with SFA disease typically undergo an endovascular intervention first, there are patients who may benefit from alternate treatments. Specifically, a younger patient with a usable vein will likely be better served by initial femoropopliteal bypass due to improved patency. For patients with long-segment SFA disease and unfavorable anatomy for

native SFA recanalization, primary PTAB may be a good option in these patients who would otherwise have limited options. Additionally, patients with claudication who are actively smoking have worse outcomes after any revascularization procedure and may be best served by conservative management until smoking cessation is achieved.

**After how many endovascular attempts do you seek an alternative like open femoropopliteal bypass surgery? What do you do for those who cannot receive surgery?**

There is no universal number of failed endovascular procedures prior to considering open surgery that will apply to all patients; however, in certain patients who have failed endovascular procedures in a shorter period and are deemed to have no other viable endovascular options, we strongly consider surgical bypass if they are low-risk candidates.

Patients who are at high risk for surgery and have no endovascular option for revascularization present a unique challenge in our patient population. Traditionally, we tell these patients to continue conservative treatments, which means they have to live with their lifestyle-limiting claudication. Even more concerning, if these patients have critical limb ischemia with rest pain or tissue loss, they are at risk of limb loss and major amputation. PTAB with the DETOUR System provides a potential option for this patient cohort that would otherwise have very limited options.

**In your experience, how do you predict whether an SFA patient will come back for another intervention? What clinical or anatomic characteristics would lead you to believe the patient will be a failed endovascular patient?**

There are many predictors that may lead to failed endovascular intervention and necessitates the patient returning with recurrent disease. This includes anatomic factors like longer length of lesions, severity of calcium, and poor distal runoff. Additionally, patients who have prior failed interventions or are hypercoagulable may also be at an increased risk of recurrent complications. Patients who are noncompliant with their medication and lifestyle modifications are also at an increased risk of failing endovascular and open surgical revascularization.

**Who are the ideal patients who could benefit from PTAB therapy with the DETOUR System?**

Patients with lifestyle-limiting claudication and critical limb ischemia are all potential candidates for PTAB. PTAB with the DETOUR System offers a unique solution

in patients with long-segment SFA disease. Patients with prior failed endovascular interventions who are poor surgical candidates should be considered for this therapy. Also, patients who underwent unsuccessful crossing of a long-segment SFA occlusion should be considered for PTAB.

Additionally, there are patients who present with long-segment SFA disease and no prior procedures who may be considered candidates for PTAB, including patients who may be poor candidates for traditional endovascular interventions based on anatomy. Examples of these patients include those with severe diffuse calcium of the SFA who are at high risk of rupture, rethrombosis, embolization, or stent failure. Additionally, those with thrombosed femoral or popliteal aneurysms in which recanalization may not be advisable may benefit from primary PTAB.

### What would drive you to intervene earlier and use DETOUR sooner in your treatment pathway? Specifically thinking about those patients you know will come back.

As stated previously, it is important to identify which patients are at risk of failing endovascular interventions and to consider alternate options in this cohort. In this patient population, it may be beneficial to consider using the DETOUR System, which has very promising primary patency rather than choosing a standard endovascular intervention that is likely to fail in the short term. Within the DETOUR2 investigational device exemption study,

primary patency\* was 81.8% and 69.1% through 12 and 24 months, respectively. Freedom from clinically driven target lesion revascularization was 87.7% and 76.7% through 12 and 24 months, respectively.<sup>1,2</sup>

### How/when do you follow-up with these patients? How do these patients differ in follow-up from other treatment options, if at all? How do you customize patient follow-up based on lifestyle and needs?

We follow a similar protocol to patients undergoing a standard endovascular procedure. The majority of patients undergoing PTAB are placed on dual antiplatelet therapy postoperatively, with anticoagulation reserved for high-risk patients. We typically see patients who had PTAB 2 to 4 weeks after their procedure for the first postoperative visit. At this visit, we will get arterial testing, which includes an arterial duplex ultrasound and ankle-brachial index to ensure the patency of the TORUS Stent Grafts (Endologix). If the patient is recovering well, we generally follow-up every 3 to 6 months thereafter with a surveillance duplex at every visit. If they require wound care, they will be seen much more frequently until wound healing has been achieved. ■

#### \*SVS primary patency definition.

1. Lyden SP, Soukas PA, De A, et al. DETOUR2 trial outcomes demonstrate clinical utility of percutaneous transmural bypass for the treatment of long-segment, complex femoropopliteal disease. *J Vasc Surg.* 2024;79:1420-1427. e2. doi: 10.1016/j.jvs.2024.02.004
2. Adams, G. Durability of Percutaneous Bypass for Treatment of Femoropopliteal Disease: Two-year outcomes of the DETOUR-2 study. Presented at: Amputation Prevention Symposium (AMP); August 16-19, 2023; Chicago, Illinois.

#### INDICATIONS FOR USE:

The DETOUR™ System is indicated for use for percutaneous revascularization in patients with symptomatic femoropopliteal lesions from 200 mm to 460 mm in length with chronic total occlusions (100 mm to 425 mm) or diffuse stenosis > 70% who may be considered suboptimal candidates for surgical or alternative endovascular treatments. The DETOUR™ System, or any of its components, is not for use in the coronary and cerebral vasculature.

#### CONTRAINDICATIONS:

The DETOUR™ System is contraindicated in patients with:

- A distal common femoral artery (CFA) < 7 mm in diameter.
- Increased risk of deep vein thrombosis (DVT), such as patients with a recent history of DVT, thrombophilia, and disseminated malignancy.
- Untreated flow-limiting aortoiliac occlusive disease.
- Lack of patent single vessel tibial runoff to ankle.
- Known coagulopathy, bleeding diathesis, or thrombocytopenia that cannot be medically managed.
- Known hypersensitivities, allergies or contraindications to: Nitinol; PTFE; aspirin; heparin; antiplatelet; anticoagulant or thrombolytic therapy; or contrast media that cannot otherwise be medically managed.

Refer to Instructions for Use for more information concerning Indications, Contraindications, Specific Anatomic Considerations, Warnings, Precautions, and Adverse Events.

**CAUTION:** Federal (USA) law restricts this device to sale by or on the order of a physician.

**NOTE:** Not all product components are available in every country. Please consult with your Endologix representative to confirm product availability.

Endologix® is a registered trademark of Endologix LLC in the United States, Europe and Japan. All other trademarks are the property of their respective owners.

©2024 Endologix LLC. All rights reserved. MM2825-US Rev 01